

# Myoclonus in Childhood

Michael R. Pranzatelli

The term “myoclonus” sounds esoteric, yet it is part of our normal physiology, occurring as a muscle jerk on drowsiness or falling asleep, during rapid eye movement (REM) sleep, and as hiccoughs. Myoclonus is also a developmental feature of the human nervous system, comprising some of the earliest fetal movements. In pathologic settings, myoclonus may be the only neurologic abnormality, as in essential myoclonus, but more often it is one symptom of a larger neurologic problem. The vast etiologic spectrum of symptomatic myoclonus can be bewildering, but defining the underlying problem may provide the opportunity to develop specific therapies. Otherwise, treatment is merely symptomatic. The approach to the patient should be to verify the nature of the movement disorder and establish a specific etiologic diagnosis. A battery of neurophysiologic, neuroradiologic, and other laboratory studies is needed to localize the origin of the myoclonus and identify causative lesions. Drug treatment is largely empiric but must be systematic and aimed at restoring activities of everyday living. Unlike in epilepsies, in myoclonus multiple drugs usually must be combined to attain functional improvement.

© 2003 Elsevier Inc. All rights reserved.

**M**YOCLONUS IS a brief involuntary muscle jerk originating in the central nervous system.<sup>1</sup> It is a paroxysmal event that may appear as an isolated finding or as a symptom of many diseases. Myoclonus affects all age groups and may be so severe as to be disabling or may be mild and require no treatment. Developmental and physiologic forms of myoclonus contribute to its uniqueness as a dyskinesia.<sup>2</sup> Physiologic myoclonus occurs episodically throughout life as hiccoughs (singultus) and hypnic (sleep) jerks. Myoclonus is also distinguished from other movement disorders by its unusual association with epilepsy and ataxia and by the distinctive panel of drugs used in its treatment. This article focuses on recent advances in classification, etiology, diagnosis, and treatment of myoclonus.

## CLASSIFICATION

Rather than one biologically “generic” myoclonus, there are several types. Different classification schema have been proposed, ranging from purely clinical classifications to those that use etiologic or neurophysiologic criteria (Table 1).<sup>1</sup>

Differentiation between spontaneous, reflex, and movement-induced action myoclonus can be made clinically. The most common of these types is action myoclonus. Myoclonus may be activated by the intention of an action or the action itself. Reflex myoclonus is activated by sound, light, touch, or passive movement of a limb.

Patients with myoclonus may exhibit postural lapses that correspond to a silent period on electromyography (EMG). This brief lack of muscle activity that sometimes follows a muscle discharge has been called “negative myoclonus,” or asterixis, in contradistinction to the muscle discharges de-

noted as “positive myoclonus”.<sup>3</sup> Sudden loss of antigravitational muscle tone can be disabling and refractory to treatment. Many patients with severe myoclonus have a mixture of positive and negative myoclonus.

Cortical, subcortical, and spinal myoclonus are defined neurophysiologically, but there are clinical clues as well (Table 2).<sup>4</sup> Cortical myoclonus is focal and distal and typically found in the arm. Cortical reflex myoclonus may be activated by photic stimulation. Patients with subcortical myoclonus have both proximal and distal generalized myoclonus, involving both agonist and antagonist muscle groups. Spinal myoclonus may be limited to muscles innervated by a few or multiple spinal segments and affects predominantly flexor muscles.<sup>1</sup>

These myoclonic categories can also be classified as epileptic or nonepileptic (Table 3).<sup>3,4</sup> Cortical reflex myoclonus, reticular reflex myoclonus, and the myoclonic jerks that herald a generalized seizure in patients with primary generalized epilepsy are examples of epileptic myoclonus.<sup>4</sup> Nonepileptic myoclonus encompasses normal physio-

---

*From the Departments of Neurology and Pediatrics, Southern Illinois University School of Medicine, Springfield, IL.*

*Supported by the American Medical Association Research and Education Foundation, Florence A. Carter Fellowship; the Children's Miracle Network; and the Southern Illinois University School of Medicine.*

*Address reprint requests to Michael R. Pranzatelli, MD, National Pediatric Myoclonus Center, Southern Illinois University School of Medicine, P.O. Box 19658, Springfield, IL 62702.*

© 2003 Elsevier Inc. All rights reserved.

1071-9091/03/1001-0007\$30.00/0

doi:10.1053/spen.2003.0000

**Table 1. Classification of Myoclonus**

<i>Clinical</i>		
Activation	Regularity	Synchrony
Spontaneous	Rhythmic	Synchronous
Sensory-evoked	Arrhythmic	Asynchronous
Action-evoked	Oscillatory	
Distribution	Direction of joint displacement	
Focal	Upward	
Multifocal	Downward	
Generalized		
<i>Etiologic</i>		
Essential	Developmental	
Symptomatic	Physiologic	
Genetic disorders	Hiccups	
Acquired disorders	Hypnic jerks	
	Fragmentary nocturnal myoclonus	
<i>Neurophysiologic</i>		
Localization		
Cortical	Subcortical	
Cortical reflex	Reticular reflex	
Spontaneous cortical	Spontaneous reticular	
Epilepsy partialis continua	Ballistic overflow	
Cortico-reticular	Oscillatory	
	Cortico-subcortical	
	Spinal	
Relation to muscle tone		
Positive		
Negative		
Relation to epilepsy		
Epileptic	Non-epileptic	
Cortical reflex	Exaggerated startle	
Reticular reflex	Periodic movements of sleep	
Primary generalized epileptic	Myoclonic tics	
	Segmental myoclonus	
	Physiologic myoclonus	

logic phenomena, exaggerated startle, periodic movements of sleep, some tics, essential myoclonus, and dystonic and segmental myoclonus.

#### DIFFERENTIAL DIAGNOSIS

Myoclonus is differentiated from superficially similar dyskinesias by its abruptness and brevity (Fig 1). Although myoclonus is sometimes confused with tics, which are commonly myoclonic in nature, tics are usually confined to the head and

shoulders and may be more complex in pattern. Choreiform movements in the fingers when the hands are held outstretched may also appear myoclonic, but myoclonus is not typically limited to the fingers. When multiple dyskinesias are present, ancillary tests may be necessary to distinguish between them.

Although the term "palatal myoclonus" has been used for many years to describe the rapid, rhythmic fluttering of the soft palate, newer studies indicate

**Table 2. Differentiation of Cortical and Subcortical Myoclonus**

	Cortical Myoclonus	Subcortical Myoclonus
Pattern	Focal	Generalized
Location	Distal	Proximal and distal
Muscle group	One synergist group	Agonist-antagonist cocontraction
Activation	Rostrocaudal activation order	May propagate up brainstem
EEG	Time-locked	Not time-locked
SSEPs	"Giant" (enhanced)	Normal amplitude

**Table 3. Relation of Myoclonus to Epilepsy**

Type	EMG Burst Length (msec)	
	Positive myoclonus	Negative myoclonus
Epileptic	<50	≤400
Non-epileptic	50-200	200-500

that “palatal tremor” is a more appropriate term. Periodic movements of sleep have sometimes been confused with “nocturnal myoclonus,” which instead should refer to myoclonic jerks, such as fragmentary myoclonus, during different phases of sleep.<sup>5</sup> The movements of restless legs are not truly myoclonic and are distinguished by the associated sensations. While startle is a component of brainstem myoclonus, startle disorders such as hyperplexia are discrete syndromes. It also has been suggested recently that essential myoclonus and myoclonus dystonia, both of which are sensitive to ethanol, are manifestations of the same disorder. Although the term “cortical tremor” implies a non-myoclonic disorder, this is actually a form of cortical reflex myoclonus that looks similar to essential tremor but is found in patients with myoclonus.<sup>6</sup>

**ETIOLOGIES**

The treatable or reversible etiologies of myoclonus need to be recognized (Table 4), especially iatrogenic causes.<sup>2,7-14</sup> Too many diseases associated with myoclonus are not yet reversible. These include degenerative disorders (eg, Rett’s syndrome, leukodystrophies and Hallervorden-Spatz disease), metabolic disorders (eg, certain aminoacidurias, lysosomal storage diseases, Leigh’s syndrome, and lipidoses), neurocutaneous disorders (eg, tuberous sclerosis, Sturge-Weber syndrome, and linear nevus sebaceum), prion diseases (eg, slow virus infections), congenital brain anomalies (eg, dorsal and ventral induction defects, migrational and proliferation disorders, porencephaly, hydranencephaly, and agenesis of corpus callosum), and severe acquired disorders, such as head or spinal injury. Myoclonus is usually one of many neurologic abnormalities seen in these disorders.

**CONTEXT-SPECIFIC MYOCLONUS**

Identifying the specific context in which myoclonus occurs aids diagnosis and helps organize the otherwise unruly heterogeneity of etiologies asso-

ciated with myoclonus (Fig 2). It is fashionable to designate “dyskinesia-plus” syndromes in the etiologic classification of other movement disorders, and myoclonus is amenable to the same approach.

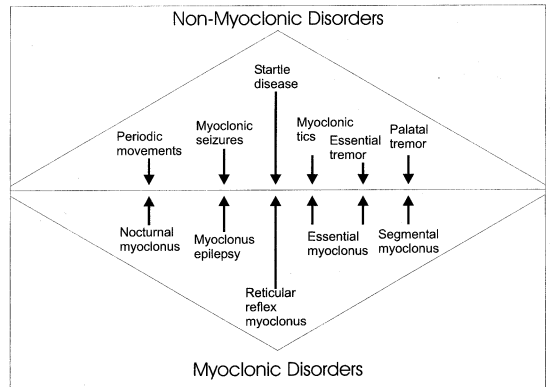
**Sleep Myoclonus**

The term “benign neonatal sleep myoclonus” includes all of the component features of this context-specific myoclonus. The diagnosis is confirmed by waking the infant, which stops the myoclonus, or through proprioceptive input by tapping on the limbs, which increases or elicits the jerks.<sup>15</sup> When the myoclonus is rhythmic, the onset is late, or the syndrome persists, the diagnosis may be missed. Electroencephalography (EEG) findings are normal.<sup>16</sup>

Myoclonus is part of normal sleep physiology, as paradoxical excitation in rapid-eye-movement sleep. Beginning in fetal life, this is most abundant during the first 6 to 8 months postnatal and persists through life as fragmentary nocturnal myoclonus. Hypnic jerks, or myoclonus on sleep initiation, are associated with the sensation of falling.

**Isolated Myoclonus During Wakefulness in Otherwise Normal Children**

Essential myoclonus occurs in otherwise normal individuals and has an upper body distribution similar to that of myoclonic tics, with which it is most often confused. “Benign myoclonus of early infancy” is a term coined to designate nonepileptic “spasms” that otherwise resemble West’s syndrome.<sup>17</sup> Developmental and neurologic examina-



**Fig 1. The interface of myoclonus and related disorders not properly designated as myoclonus. The pathophysiologic relationship of some entities is poorly understood and controversial.**

**Table 4. Potentially Reversible Causes of Myoclonus**

Category	Example
Cofactor deficiency	Biotin, pyridoxine, cobalamin (congenital or infantile)
Drugs/intoxications	Psychotropic medications, antibiotics, insecticides, phenytoin, carbamazepine, anesthetics, narcotics, dopaminergic drugs; antineoplastic drugs, cardiovascular drugs, toxins (strychnine, lead)
Infections	Meningitis, encephalitis (EBV, Coxsackie B), HIV, group A beta-hemolytic streptococcal pharyngitis
Metabolic disorders	Uremia, hepatic failure, electrolyte disturbance, hypoglycemia, aminoacidurias, urea cycle disorders, organic acidurias, Wilson disease†
Tumors (non-CNS)	Paraneoplastic disorders

†More typically manifests dystonia or chorea

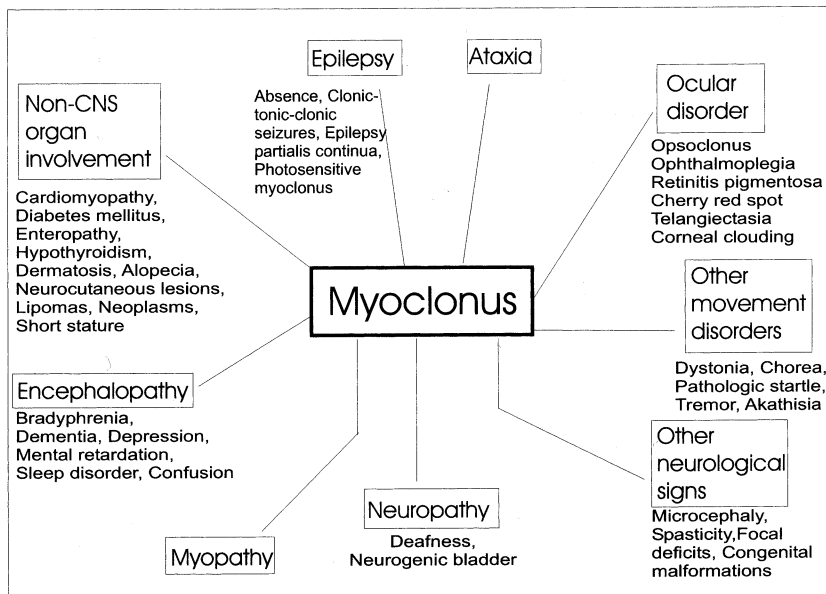
tion findings are normal, no treatment is required, and the prognosis is excellent. Self-limited myoclonus also occurs in normal children in the setting of fever.<sup>18</sup>

**Myoclonus and Opsoclonus**

The opsoclonus-myoclonus syndrome (OMS) is a neuroblastoma-associated paraneoplastic disorder of toddlers. Opsoclonus, also called “dancing eyes,” refers to conjugate, darting eye movements. The myoclonus occurs principally with action, but also spontaneously and reflexively. Other features are ataxia, dysarthria, behavior problems, sleep disturbance, and cognitive impairment. The brain is caught in the “crossfire” of the immune system’s attack on the tumor, which shares as-yet unidentified onconeural antigens.<sup>19</sup>

**Myoclonus and Epilepsy**

Progressive myoclonus epilepsy (PME) is a myoclonic syndrome of childhood or adolescence. Common to all of the etiologies of PME is the combination of myoclonus and epilepsy and a progressive course, with a variable rate of progression. Ataxia and dementia are associated features in some types. The myoclonus affects speech and gait, is action- and stimulus-sensitive, and also occurs spontaneously.<sup>20</sup> Although epileptic seizures may be the initial presentation, these gradually subside on treatment, but the myoclonus becomes relentless. The major types of PME are Unverricht-Lundborg disease (EPM1), mitochondrial encephalomyopathy, and Lafora disease.<sup>21</sup> EPM1 may be compatible with a normal life span,



**Fig 2. Relation of myoclonus to other clinical signs in “myoclonus-plus” syndromes of pediatric onset.**

whereas the other two types are typically fatal in the second decade of life. Both occur sporadically or due to autosomal-recessive inheritance. Patients with EPM1 tend to have absence or tonic-clonic seizures, whereas those with Lafora disease may have clonic-tonic-clonic seizures or partial epilepsy.<sup>22</sup> Many clinical features differentiate other types of PME.<sup>23-25</sup>

Juvenile myoclonus epilepsy (JME) represents primary generalized epilepsy in which myoclonic jerks occur independently of seizures, particularly on awakening.<sup>26</sup> JME is sometimes confused with PME. Reference to it as "myoclonic epilepsy" is a misnomer.

Because myoclonic seizures are a type of epilepsy, this author does not include them in discussions of myoclonus as a movement disorder.<sup>27</sup> However, some authors do so.<sup>25,28,29</sup>

### Myoclonus and Ataxia

Myoclonus in the context of cerebellar ataxia is often part of a progressive disorder, such as ataxia-telangiectasia,<sup>30</sup> in which case other dyskinesias may be present as well. Progressive myoclonus ataxia (PMA), previously known as Ramsay-Hunt syndrome, may represent more than one disorder.

### Myoclonus and Dystonia

The combination of myoclonus and dystonia without other abnormalities should suggest myoclonus-dystonia, a genetic entity.<sup>31</sup> Ethanol responsiveness and autosomal-dominant inheritance have been described.

### Myoclonus and Toxic Encephalopathy

The so-called "serotonin syndrome" is an uncommon but potentially lethal drug reaction occurring primarily in patients with psychiatric illness during treatment with serotonin reuptake inhibitors and other serotonin-potentiating agents.<sup>32</sup> Serotonin syndrome is the prototype of drug-induced myoclonus. Patients also exhibit fever, confusion, restlessness, ataxia, hyperreflexia, and tremor.

## PATHOPHYSIOLOGY

### Anatomy and Circuitry

Because myoclonus is often one feature of a more diffuse neurologic disorder, the gamut of neuropathologic lesions has obscured what might be an anatomic common denominator to myoclo-

nus. In cortical myoclonus, lack of inhibition facilitates the transcallosal and cortical spread of myoclonus.<sup>4</sup> Abnormal activation of the sensorimotor cortex gives rise to cortical myoclonus, but whether abnormalities of both cortices are requisite remains controversial.

Brainstem myoclonus can be induced in experimental animals by injection of various drugs into the brainstem reticular formation at the nucleus gigantocellularis reticularis or anatomically related structures, such as the inferior olive. This medullary reticular region has also been implicated in the paradoxically excitatory manifestation of myoclonus during REM sleep. The most common forms of brainstem myoclonus appear to utilize the same circuitry as the normal startle reflex.<sup>33</sup>

The propriospinal system may be involved in some forms of spinal myoclonus. A spinal-stepping generator has been proposed that may be released from supraspinal control.

Noninvasive functional neuroimaging should provide some answers to the questions regarding the circuitry involved in myoclonic disorders. Some of the subcortical structures involved, especially in the brainstem, are difficult to resolve using current technology. In hereditary essential myoclonus, cerebral blood flow studies have revealed reduced cortical cerebral blood flow contralateral to the myoclonus, suggesting a brainstem or basal ganglia lesion. In epileptic negative myoclonus, EEG-single-photon emission computed tomography (SPECT) indicates involvement of the premotor cortex.<sup>34</sup>

### Neurotransmitters

Experiences with myoclonus-evoking drugs and intoxications, the therapeutic use of many pharmacologically diverse categories of drugs, and cerebrospinal fluid (CSF) studies of neurotransmitters or their metabolites, have implicated more than one neurotransmitter system in human myoclonic disorders.<sup>35</sup> Without yet being able to identify which neurotransmitter is most proximal to the myoclonus induction mechanism, it is possible to say that  $\gamma$ -aminobutyric acid (GABA), glycine, serotonin, and glutamate seem to be primary.

Although the idea that various types of myoclonus involve different neurotransmitters locally and through projections because they involve different anatomic pathways is plausible, very little data are available in humans. Distinctive pharmacologic

responses in diverse types of myoclonus may be based on unique circuitry of cortical, brainstem, and spinal myoclonus "generators," as well as the functional impact of specific human myoclonic disorders on the anatomy and physiology of that circuitry. In spinal cords of experimental animals, local circuitry includes GABA- and glycine-mediated inhibition of Renshaw cells on spinal motor neurons. Neurotransmitter receptor subunit and ion channel disorders may be involved in some forms of hereditary myoclonus.

### Animal Models

Gene knockout animal models of myoclonus are allowing links to be made between gene defects and brain neuropharmacology. Of note are recent models of EPM1,<sup>36</sup> neuronal ceroid lipofuscinosis,<sup>37</sup> and mitochondrial disorders.<sup>38</sup> Profound loss of GABA-ergic interneurons and an autoantibody inhibitory to glutamic acid decarboxylase (GAD) are new findings in neuronal ceroid lipofuscinosis.<sup>39,40</sup> Mice lacking potassium channels Kv3.1 and Kv3.3 display myoclonus.<sup>41</sup>

## LABORATORY TESTS

### Neurophysiologic Studies

Cortical, subcortical, and spinal myoclonus can be differentiated by computer-facilitated back-averaging, which correlates EEG and electromyography (EMG) activity. A cortical electrical potential occurs just before the myoclonic jerk in cortical, but not subcortical, myoclonus.<sup>42</sup> Besides this time-locked EEG event, patients with cortical myoclonus have enlarged somatosensory evoked potentials (SSEPs) and enhanced long loop reflexes.<sup>6</sup> Advanced magnetograms, which have three-dimensional resolution, have aided localization of the premyoclonus spike in cortical myoclonus, resolving the giant somatosensory evoked magnetic field to the sensory or motor cortex.<sup>33</sup> Cortical myoclonus is typical of PME, Angelman syndrome, and autosomal-dominant cortical myoclonus and epilepsy.<sup>23,43,44</sup>

In subcortical myoclonus, SSEPs are normal, and muscle group activation indicates that discharges may actually propagate up the brainstem. A common type of subcortical myoclonus is reticular reflex myoclonus.<sup>4</sup>

Epileptic and nonepileptic myoclonus can be differentiated on EEG and EMG testing. The EMG

burst in epileptic myoclonus is very short, and there is an EEG correlate. The innervation of muscles involved in jerking is synchronous, and the muscle groups affected may be activated either in a rostrocaudal or ascending fashion.<sup>4</sup> In contrast, nonepileptic myoclonus is associated with longer EMG discharges and asynchronous muscle group jerking. Muscles are activated in a segmental fashion without an EEG correlate.<sup>1</sup>

Evoked potentials differentiate two types of myoclonus: one with and another without enhanced SSEPs. Physiologic myoclonus, such as during sleep or startle, occurs without an enhanced evoked potentials. Giant SSEPs occur in the epilepsies, including myoclonic generalized seizures.<sup>33</sup>

### Neuroimaging Studies

Magnetic resonance imaging or computed tomography scans of the head or spinal cord are normal in essential myoclonus and in some types of symptomatic myoclonus. SPECT may demonstrate hypoperfusion associated with myoclonus.<sup>21,45,46</sup> MR spectroscopy may be positive when other studies are negative.

### Other Tests

Sophisticated biochemical and histochemical tests enable a specific etiologic diagnosis. They may include biotinidase, biotin, organic and amino acids, urinary oligosaccharides, as well as evoked responses, skin biopsy, slit-lamp examination, muscle biopsy, and electroretinography.<sup>47</sup> Antineuronal antibodies and antibodies to neurotransmitter pathway enzymes, such as GAD, can be measured. Determination of catecholamine precursors and metabolites in CSF may be helpful in diagnostically challenging cases.<sup>48</sup> Advances in the molecular genetics of movement disorders have produced new diagnostic tests (Table 5).<sup>24,26,31,36,44,49-59</sup> Pediatric rating scales for the evaluation of myoclonus are available.<sup>60,61</sup>

## TREATMENT OF MYOCLONUS

Treatment of the underlying pathophysiology is preferable to symptomatic treatment. In drug-induced myoclonus, the offending agent should be stopped and symptomatic support given. The approach to myoclonus due to infections is directed to the source of the infection. When myoclonus occurs as the remote immunologic effect of can-

**Table 5. Some Genetic Disorders Associated with Myoclonus**

Disorder	Chromosome	Gene/Gene Product
ADCME	2p11.1-q12.2	—
Angelman syndrome	15q11-q13	UBE3A, GABRB3(?)
Ataxia-telangiectasia	11q	ATM
NCL	16p12	CLN1, CLN2, CLN3/lysosomal enzymes and transmembrane proteins
Biotinidase deficiency	3p25	BTD gene/biotinidase
DRPLA	12p	DRPLA gene/atrophin-1
JME	6p, 15q	—
Mitochondrial		
MERRF		mt RNA (Lys)
MELAS		mt RNA (Leu (UUR))
PEO		multiple point mutations and large deletions
Myoclonus-dystonia syndrome (DYT11)	7q21-q31	SGCE (gene for epsilon-sarcoglycan)
	11q23	D <sub>2</sub> dopamine receptor gene (?)
PME		
U-L disease (EPM1)	21q22.3	CSTB/cystatin B
Lafora (EPM2)	6q23-q25	EPM2A/laforin
GM1-gangliosidosis	5p1.13	Beta-galactosidase gene
Sialidosis, type 1	20	Sialidase gene
Juvenile Gaucher (type III)	1.q21	Glucocerebrosidase gene
SCA 2	12	SCA2 gene/ataxin-2

ADCME, autosomal dominant cortical myoclonus and epilepsy

DRPLA, dentato-rubro-pallido-luysian atrophy

JME, juvenile myoclonic epilepsy

MERRF, mitochondrial encephalopathy with ragged red fibers

MELAS, mitochondrial encephalopathy with lactic acidosis and stroke-like episodes

NCL, neuronal ceroid lipofuscinosis

PME, progressive myoclonus epilepsy

SCA, spinocerebellar ataxia

cers, the therapy is aimed at the cancer and also against the autoimmune process.<sup>19</sup>

### Anticonvulsants

Anticonvulsants (Table 6) are the mainstay of treatment for myoclonus, whether it is epileptic or nonepileptic.<sup>12,22,62-64</sup> The 1,3-substituted benzodiazepines clonazepam, nitrazepam, and lorazepam are particularly useful due to the combination of their anxiolytic, sedative, muscle relaxant, and anticonvulsant properties, but tolerance is limiting.<sup>35</sup> Anticonvulsants may have synergistic effects in myoclonus. However, not all are antimyoclonic, and some induce myoclonus.<sup>65-71</sup>

### Immunotherapy

Immunomodulation with intravenous immunoglobulins is an important treatment for myoclonus due to autoimmune disorders. Immunosuppressants, such as azathioprine, cyclophosphamide, and methotrexate, also have a role. Adrenocorticotrophic hormone is still the gold standard for OMS.

Case reports suggest that plasmapheresis also may be effective.<sup>72</sup>

### Cofactors and Vitamins

Cofactors and vitamins are used to reverse underlying etiologic abnormalities. Coenzyme-Q and carnitine may be administered in mitochondrial myopathies. Although biotin's mechanism of action in myoclonus remains uncertain, replacement therapy may be therapeutic in deficiencies of biotinidase, multiple carboxylases, or other biotin-dependent enzymes.<sup>47</sup> A response to biotin may occur in the absence of biotin or biotinidase deficiency. Response to thiamine in opsoclonic cerebellopathy has been reported but is rare.

### Other Drugs

Anticholinergic drugs (eg, trihexyphenidyl) are an option in treating myoclonus dystonia but have a limited role in the therapy of other myoclonic disorders. Estrogen may be either a cause of or a treatment for movement disorders,<sup>73</sup> but when menstrual peri-

Table 6. Antiepileptic Drugs and Myoclonus

Effect	Comment
<i>Antimyoclonic</i>	
Phenobarbital	Broad-spectrum; good for status myoclonus
Primidone	Good for essential myoclonus
Clonazepam	Effective against opioid-induced myoclonus
Valproate	Best drug for EPM1; good for JME
Levetiracetam	Good for cortical myoclonus; avoid in mood and behavior disorders
Topiramate	Anorexic effect may offset obesity in non-ambulatory patients
Felbamate	For refractory myoclonus in youngsters
Ethosuximide	For epileptic negative myoclonus
Zonisamide	For PME
<i>Occasionally myoclonic</i>	
Gabapentin	In chronic refractory epilepsy; good for opioid-induced myoclonus
Lamotrigine	In intractable generalized epilepsy and Lennox-Gastaut; less often in JME
Lorazepam	In infants
Pregabalin	In epileptic patients
Vigabatrin	In epileptic patients
<i>Best Avoided</i>	
Phenytoin	Worsens EPM1; used for diaphragmatic myoclonus
Carbamazepine	Myoclonus induced in BECTS

BECTS, benign epilepsy with centrotemporal spikes

EPM1, epilepsy, progressive myoclonus, type 1

JME, juvenile myoclonus epilepsy

PME, progressive myoclonus epilepsy

ods exacerbate myoclonus, the use of oral contraceptives may improve the situation. Dextromethorphan, a weak noncompetitive inhibitor at the dissociative anesthetic site within the ion channel associated with the N-methyl-D-aspartate (NMDA) glutamate receptor, has been used for nonketotic hyperglycinemia. In progressive myoclonus ataxia, acetazolamide may be useful as adjunctive therapy.

The serotonin precursor 5-hydroxy-L-tryptophan (L-5-HTP) may be useful when conventional drugs have failed in posthypoxic myoclonus and photic cortical reflex myoclonus. L-5-HTP is not antimyoclonic in all types of myoclonus, having a rather limited role in PME<sup>20</sup> and in OMS. It may induce the eosinophilia-myalgia syndrome. L-5-HTP is administered with the peripheral decarboxylase inhibitor carbidopa to limit side effects, such as cramping and diarrhea. There is a rationale basis for the use of serotonin receptor agonists and antagonists in myoclonic disorders,<sup>32</sup> but this area is largely unexplored.

Piracetam is a first-generation prototype nootropic drug found by serendipity to be antimyoclonic only in cortical myoclonus.<sup>74</sup> Despite the high doses required,<sup>75</sup> the safety index is excellent in children.<sup>61</sup> Levetiracetam has lesser antimyoclonic effect but more antiepileptic activity.<sup>76</sup> Both

have a role in the treatment of PME<sup>77</sup> and posthypoxic myoclonus.<sup>78</sup>

Lisuride and apomorphine have been used in the treatment of cortical reflex myoclonus. Although apomorphine acts as a dopamine agonist, lisuride has both serotonergic and dopaminergic properties. Tetrabenazine is a dopamine antagonist and dopamine storage depletor used occasionally to treat spinal myoclonus.

Baclofen, a GABA agonist, has been used in difficult or refractory cases of myoclonus such as spinal myoclonus or the EPM1 type of PME. Chloral hydrate may be used acutely or chronically in the treatment of refractory myoclonus in PME.<sup>79</sup> Midazolam infusion may allow the continuation of long-term high-dose morphine for pain control in cancer patients even in the presence of morphine-induced myoclonus. One treatment for essential myoclonus is a beta-blocker without intrinsic sympathomimetic activity, such as propranolol or the selective beta-blockers metoprolol or nadolol.

### Botulinum Toxin

Botulinum toxin injection temporarily alleviates painful myoclonus.<sup>80</sup> In preventing the release of acetylcholine at the neuromuscular junction, it may



block involuntary movement but will preserve strength. The effects last from weeks to months, but the injections can be repeated. Both botulinum toxins A (Botox) and B are used clinically. The current trend is toward lower doses than those recommended initially.

### Transcranial Magnetic Stimulation

Transcranial magnetic stimulation (TMS) is a noninvasive, safe, and painless way to stimulate the human motor cortex in humans.<sup>81</sup> Types include single-pulse, paired-pulse, and repetitive

TMS (rTMS).<sup>82</sup> rTMS can be used to transiently inactivate different cortical areas to study their functions. Modulation of cortical excitability by rTMS has therapeutic potential in neurologic and psychiatric disorders, because high-frequency rTMS (5 Hz) increases cortical excitability, whereas low-frequency stimulation (1 Hz) reduces cortical excitability.<sup>83</sup> Although only cortical structures are currently accessible, TMS seems capable of affecting activity in cortically linked deep brain structures.<sup>84</sup> The only serious side effect is a possible induction of seizures.<sup>85</sup>

### REFERENCES

- Marsden CD, Hallett M, Fahn S: The nosology and pathophysiology of myoclonus, in Marsden CD, Fahn S (eds): *Movement Disorders*. London, Butterworths, 1982, pp 196-248
- Pranzatelli MR: Myoclonic disorders. *Pediatr Ann* 22:33-37, 1993
- Tassinari CA, Rubboli G, Parmeggiani L, et al: Epileptic negative myoclonus. *Adv Neurol* 67:181-197, 1995
- Hallett M: Myoclonus: Relation to epilepsy. *Epilepsia* 26:567-577, 1985
- Anstead M: Pediatric sleep disorders: New developments and evolving understanding. *Curr Opin Pulm Med* 6:501-506, 2000
- Toro C, Pascual-Leone A, Deuschl G, et al: Cortical tremor: A common manifestation of cortical myoclonus. *Neurology* 43:2346-2352, 1993
- DiFazio MP, Morales J, Davis R: Acute myoclonus secondary to group A beta-hemolytic streptococcus infection: A PANDAS variant. *J Child Neurol* 13:516-518, 1998
- Maitech M, Daoud AS: Myoclonic seizure following intravenous verapamil injection: Case report and review of the literature. *Ann Trop Paediatr* 21:271-272, 2001
- Grech V, Vella C, Mercieca V: Temporary myoclonus with treatment of congenital transcobalamin 2 deficiency. *Pediatr Neurol* 24:75-76, 2001
- Ozer EA, Turker M, Bakiler AR, et al: Involuntary movements in infantile cobalamin deficiency appearing after treatment. *Pediatr Neurol* 25:81-83, 2001
- McClain BC, Probst LA, Pinter E: Intravenous clonidine use in a neonate experiencing opioid-induced myoclonus. *Anesthesiology* 95:549-550, 2001
- Mercadante S, Villari P, Fulfaro F: Gabapentin for opioid-related myoclonus in cancer patients. *Support Care Cancer* 9:205-206, 2001
- Zaw W, Knoppert DC, da Silva O: Flumazenil's reversal of myoclonic-like movements associated with midazolam in term newborns. *Pharmacotherapy* 21:642-646, 2001
- Ghaziuddin N, Iqbal A, Khetarpal S: Myoclonus during prolonged treatment with sertraline in an adolescent patient. *J Child Adolesc Psychopharmacol* 11:199-202, 2001
- Daoust-Roy J, Seshia SS: Benign neonatal sleep myoclonus: A differential diagnosis of neonatal seizures. *AJDC* 146:1236-1241, 1992
- Bye AM, Kok DJ, Ferenschild FT, et al: Paroxysmal non-epileptic events in children: A retrospective study over a period of 10 years. *J Paediatr Child Health* 36:244-248, 2000
- Maydell BV, Berenson F, Rothern AD, et al: Benign myoclonus of early infancy: An imitator of West's syndrome. *J Child Neurol* 16:109-112, 2001
- Rajakumar K, Bodensteiner JB: Febrile myoclonus: A survey of pediatric neurologists. *Clin Pediatr (Phila)* 35:331-332, 1996
- Pranzatelli MR: Paraneoplastic syndromes: An unsolved murder. *Semin Pediatr Neurol* 7:118-130, 2000
- Pranzatelli MR, Tate E, Huang Y, et al: The neuropharmacology of progressive myoclonus epilepsy: Response to 5-hydroxy-L-tryptophan. *Epilepsia* 36:783-791, 1995
- Berkovic SF, Carpenter S, Evans A, et al: Myoclonus epilepsy and ragged-red fibres (MERRF), 1. A clinical, pathological, biochemical, magnetic resonance spectrographic and positron emission tomographic study. *Brain* 112(pt 5):1231-1260, 1989
- Yoshimura I, Kaneko S, Yoshimura N, et al: Long-term observations of two siblings with Lafora disease treated with zonisamide. *Epilepsy Res* 46:283-287, 2001
- Tobimatsu S, Fukui R, Shibasaki H, et al: Electrophysiological studies of myoclonus in sialidosis type 2. *Clin Neurophysiol* 60:16-22, 1985
- Tomoda A, Ikezawa M, Ohtani Y, et al: Progressive myoclonus epilepsy: Dentato-rubro-pallido-luysian atrophy (DRPLA) in childhood. *Brain Dev* 13:266-269, 1991
- Minassian BA, Sainz J, Delgado-Escueta AV: Genetics of myoclonus and myoclonus epilepsies. *Clin Neurosci* 3:223-235, 1995
- Delgado-Escueta AV, Medine MT, Serratos JM, et al: Mapping and positional cloning of common idiopathic generalized epilepsies: Juvenile myoclonus epilepsy and childhood absence epilepsy. *Adv Neurol* 79:351-374, 1999
- Pranzatelli MR: Infantile spasms vs. myoclonus: Is there a connection?, in Schwartzkroin PA, Rho JM (eds): *Epilepsy, Infantile Spasms, and Developmental Encephalopathy*. San Diego, Academic Press, 2002, pp 285-314
- Fejerman N: Myoclonus and epilepsies. *Indian J Pediatr* 64:583-602, 1997
- Oguni H, Fukuyama Y, Tanaka T, et al: Myoclonic-astatic epilepsy of early childhood: Clinical and EEG analysis of myoclonic-astatic seizures, and discussions on the nosology of the syndrome. *Brain Dev* 23:757-764, 2001

30. Pagani F, Buratti E, Stuani C, et al: A new type of mutation carries a splicing defect in ATM. *Nat Genet* 30:426-429, 2002
31. Klein C, Schilling K, Saunders-Pullman RJ, et al: A major focus for myoclonus-dystonia maps to chromosome 7q in eight families. *Am J Hum Genet* 67:1314-1319, 2000
32. Pranzatelli MR: Serotonin and human myoclonus: Rationale for the use of serotonin receptor agonists and antagonists. *Arch Neurol* 51:605-617, 1994
33. Shibasaki H: Electrophysiological studies of myoclonus. *Muscle Nerve* 23:321-335, 2000
34. Baumgartner C, Podreka I, Olbrich A, et al: Epileptic negative myoclonus: An EEG-single-photon emission CT study indicating involvement of premotor cortex. *Neurology* 46:753-758, 1996
35. Pranzatelli MR, Nadi NS: Mechanism of action of anti-epileptic and antimyoclonic drugs. *Adv Neurol* 67:329-360, 1995
36. Pennacchio LA, Lehesjoki AE, Stone NE, et al: Mutations in the gene encoding cystatin B in progressive myoclonus epilepsy (EPM1). *Science* 271:1731-1734, 1996
37. Gupta P, Sajombo AA, Atashband A, et al: Disruption of PPT1 or PPT2 causes neuronal ceroid lipofuscinosis in knockout mice. *Proc Natl Acad Sci U S A* 98:13566-13571, 2001
38. Wallace DC: Animal models for mitochondrial disease. *Methods Mol Biol* 197:3-54, 2002
39. Cooper JD, Gupta P, Bihle E, et al: Profound loss of GABAergic interneurons in the PPT1 knockout mouse model of infantile neuronal ceroid lipofuscinosis. *Neuropathol Appl Neurobiol* 28:158-159, 2002
40. Chattopadhyay S, Ito M, Cooper JD, et al: An autoantibody inhibitory to glutamic acid decarboxylase in the neurodegenerative disorder Batten disease. *Hum Mol Genet* 11:1421-1431, 2002
41. Espinosa F, McMahon A, Chan E, et al: Alcohol hypersensitivity, increased locomotion, and spontaneous myoclonus in mice lacking the potassium channels Kv3.1 and Kv3.3. *J Neurol Sci* 21:6657-6665, 2001
42. Shibasaki H, Ikeda A, Nagamino T, et al: Cortical reflex negative myoclonus. *Brain* 117:477-486, 1994
43. Guerrini R, De Lorey TM, Bonanni P, et al: Cortical myoclonus in Angelman syndrome. *Ann Neurol* 40:39-48, 1996
44. Guerrini R, Bonanni P, Patrignani A, et al: Autosomal dominant cortical myoclonus and epilepsy (ADCME) with complex partial and generalized seizures: A newly recognized epilepsy syndrome with linkage to chromosome 2p11.1-q12.2. *Brain* 124(pt 12):2459-2475, 2001
45. Oguro K, Kobayashi J, Aiba H, et al: Opsoclonus-myoclonus syndrome with abnormal single photon emission computed tomography imaging. *Pediatr Neurol* 16:334-336, 1997
46. Tanaka S, Osari S, Ozawa M, et al: Recurrent pain attacks in a 3-year-old patient with myoclonus epilepsy associated with ragged-red fibers (MERRF): A single-photon emission computed tomographic (SPECT) and electrophysiological study. *Brain Dev* 19:205-208, 1997
47. Gascon GG, Ozand PT, Brismar J: Movement disorders in childhood organic acidurias: Clinical, neuroimaging, and biochemical correlations. *Brain Dev* 16(suppl):94-103, 1994
48. Hyland K, Arnold LA, Trugman JM: Defects of bipterin metabolism and biogenic amine biosynthesis: Clinical, diagnostic, and therapeutic aspects, in Fahn S, Marsden CD, DeLong M (eds): *Dystonia 3: Advances in Neurology*, Vol 78. Philadelphia, Lippincott-Raven, 1998, pp 301-308
49. Schols L, Gispert S, Vorgerd M, et al: Spinocerebellar ataxia type 2. Genotype and phenotype in German kindreds. *Arch Neurol* 54:1073-1080, 1997
50. Besselova IN, Adkins S, Pranzatelli M, et al: Novel cystatin B mutation and diagnostic PCR assay in Unverricht-Lundborg (Baltic) progressive myoclonus epilepsy patient. *Am J Med Genet (Neuropsych Gen)* 74:467-471, 1997
51. Serratosa JM, Gomez-Garre P, Gallaredo ME, et al: A novel protein tyrosine phosphatase gene is mutated in progressive myoclonus epilepsy of the Lafora type (EPM2). *Hum Mol Genet* 8:345-352, 1999
52. Larson GP, Ding S, Lafrenier RG, et al: Instability of the EPM1 minisatellite. *Hum Mol Genet* 8:1985-1988, 1999
53. Borner GV, Zeviani M, Tiranti V, et al: Decreased aminoacylation of mutant tRNAs in MELAS but not in MERRF patients. *Hum Mol Genet* 9:467-475, 2000
54. Wisniewski KE, Kida E, Connell F, et al: Neuronal ceroid lipofuscinoses: Research update. *Neurol Sci* 21(suppl 3):549-556, 2000
55. Bonten EJ, Arts WF, Beck M, et al: Novel mutations in lysosomal neuraminidase identify functional domains and determine clinical severity in sialidosis. *Hum Mol Genet* 9:2715-2725, 2000
56. Wood JD, Nucifara FC, Duan K, et al: Atrophin-1, the dentato-rubral and pallido-luysian atrophy gene product, interacts with ETO/MTG8 in the nuclear matrix and represses transcription. *J Cell Biol* 150:939-948, 2000
57. Pshezhetsky AV, Ashmarina M: Lysosomal multienzyme complex: Biochemistry, genetics and molecular pathophysiology. *Prog Nucleic Acid Res Mol Biol* 69:81-114, 2001
58. Minassian BA: Lafora's disease: Towards a clinical, pathologic, and molecular synthesis. *Pediatr Neurol* 25:21-29, 2001
59. Zimprich A, Grabowski M, Asmus F, et al: Mutations in the gene encoding epsilon-sarcoglycan cause myoclonus-dystonia syndrome. *Nat Genet* 29:66-69, 2001
60. Tate E, Pranzatelli MR, Ho H, et al: A sensitive and semi-quantitative pediatric myoclonus evaluation scale. *Neurosci Nurs* 27:287-291, 1995
61. Pranzatelli MR, Tate ED, Galvan I, et al: Controlled pilot study of piracetam for pediatric opsoclonus-myoclonus. *Clin Neuropharmacol* 24:352-357, 2001
62. Capovilla G, Beccaria F, Veggiotti P, et al: Ethosuximide is effective in the treatment of epileptic negative myoclonus in childhood partial epilepsy. *J Child Neurol* 14:395-400, 1999
63. Moretti R, Torre P, Antonello RM: Opsoclonus-myoclonus syndrome: Gabapentin as a new therapeutic proposal. *Eur J Neurol* 7:455-456, 2000
64. Wallace SJ: Newer antiepileptic drugs: Advantages and disadvantages. *Brain Dev* 23:277-283, 2001
65. Eldridge R, Iivanainen M, Stern R, et al: "Baltic" myoclonus epilepsy: Hereditary disorder of childhood made worse by phenytoin. *Lancet* 9:838-842, 1983
66. Marciari MG, Maschio M, Spanedda F, et al: Development of myoclonus in patients with partial epilepsy during treatment with vigabatrin: An electroencephalographic study. *Acta Neurol Scand* 91:1-5, 1995
67. Guerrini R, Belmonte A, Parmeggiani L, et al: Myo-

clonic status epilepticus following high-dosage lamotrigine therapy. *Brain Dev* 21:420-424, 1999

68. Nanba Y, Maegaki Y: Epileptic negative myoclonus induced by carbamazepine in a child with BECTS: Benign childhood epilepsy with centrotemporal spikes. *Pediatr Neurol* 21:664-667, 1999

69. Asconape J, Diedrich A, DellaBadia J: Myoclonus associated with the use of gabapentin. *Epilepsia* 41:479-481, 2000

70. Janszky J, Rasonyi G, Halasz P, et al: Disabling erratic myoclonus during lamotrigine therapy with high serum level: Report of two cases. *Clin Neuropharmacol* 23:86-89, 2000

71. Huppertz HJ, Feuerstein TJ, Schulze-Bonhage A: Myoclonus in epilepsy patients with anticonvulsive add-on therapy with pregabalin. *Epilepsia* 42:790-792, 2001

72. Yiu VW, Kovithavongs T, McGonigle LF, et al: Plasmapheresis as an effective treatment for opsoclonus-myoclonus syndrome. *Pediatr Neurol* 24:72-74, 2001

73. Kompoliti K: Estrogen and movement disorders. *Clin Neuropharmacol* 22:318-326, 1999

74. Gouliayev AH, Senning A: Piracetam and other structurally related nootropics. *Brain Res Rev* 19:180-222, 1994

75. Ikeda A, Shibasaki H, Tashiro K, et al: Clinical trial of piracetam in patients with myoclonus: Nationwide multiinstitution study in Japan. *Mov Disord* 11:691-700, 1996

76. Genton P, Van Vleymen B: Piracetam and levetiracetam: Close structural similarities but different pharmacological and clinical profiles. *Epileptic Disord* 2:99-105, 2000

77. Feddi M, Reutens D, Dubeau F, et al: Long-term efficacy and safety of piracetam in the treatment of progressive myoclonus epilepsy. *Arch Neurol* 58:781-786, 2001

78. Krauss GL, Bergin A, Kramer RE, et al: Suppression of post-hypoxic and post-encephalitic myoclonus with levetiracetam. *Neurology* 56:411-412, 2001

79. Pranzatelli MR, Tate ED: Chloral hydrate for progressive myoclonus epilepsy: A new look at an old drug. *Pediatr Neurol* 25:385-389, 2001

80. Awaad Y, Tayem H, Elgamal A, et al: Treatment of childhood myoclonus with botulinum toxin type A. *J Child Neurol* 14:781-786, 1999

81. Chen, R: Studies of human motor physiology with transcranial magnetic stimulation. *Muscle Nerve Suppl* 9, S26-S32, 2000

82. Amassian VE, Cracco RQ, Maccabee PS, et al: Some positive effects of transcranial magnetic stimulation. *Adv Neurol* 67:79-104, 1995

83. Triggs WJ, Kirshner HS: Improving brain function with transcranial magnetic stimulation. *Neurology* 56:429-430, 2001

84. McDonald WM, Greenberg BD: Electroconvulsive therapy in the treatment of neuropsychiatric conditions and transcranial magnetic stimulation as a pathophysiological probe in neuropsychiatry. *Depress Anxiety* 12:135-143, 2000

85. Lisanby SH, Luber B, Sackeim HA, et al: Deliberate seizure induction with negative transcranial magnetic stimulation in nonhuman primates. *Arch Gen Psychiatry* 58:199-200, 2001